



**KVG Medical**  
*College & Hospital*  
Sullia, Karnataka

# CASE OF THE WEEK

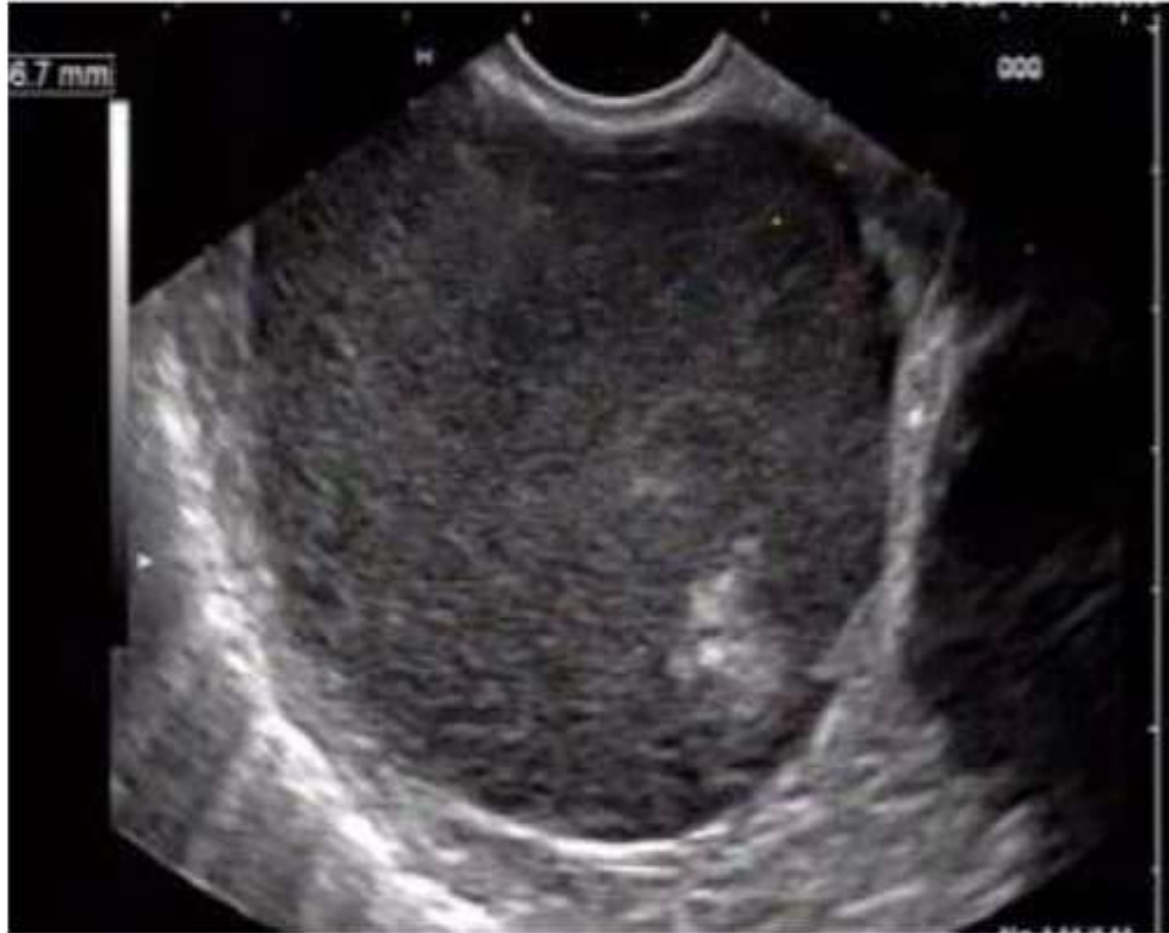**PARAGANGLIOMA**

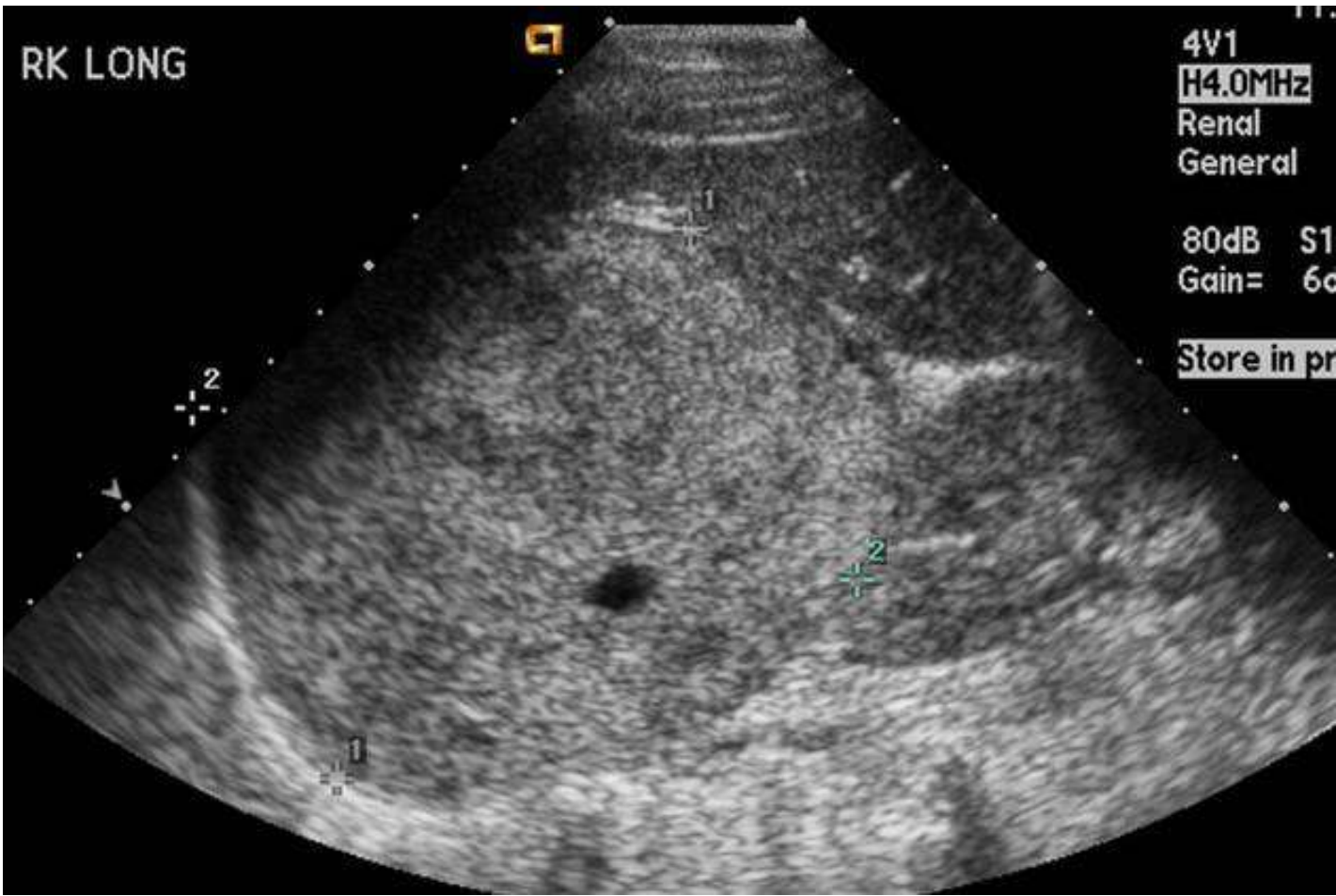
- 60 years old female with h/o

- Diffuse abdominal pain.

- Right shoulder pain.

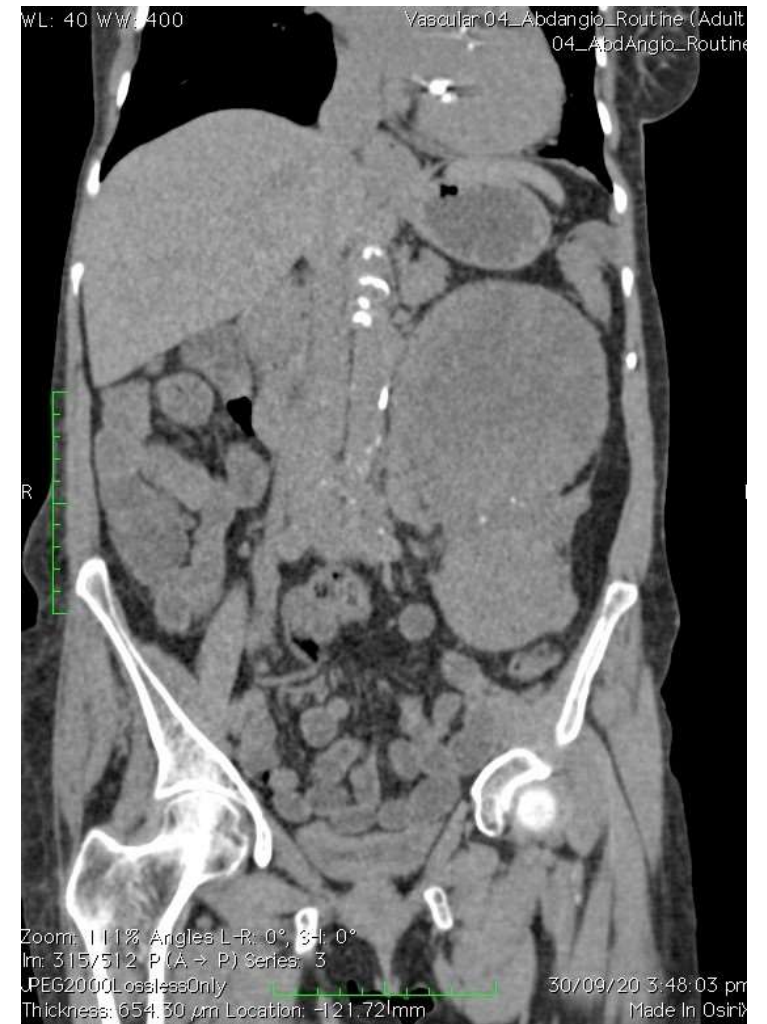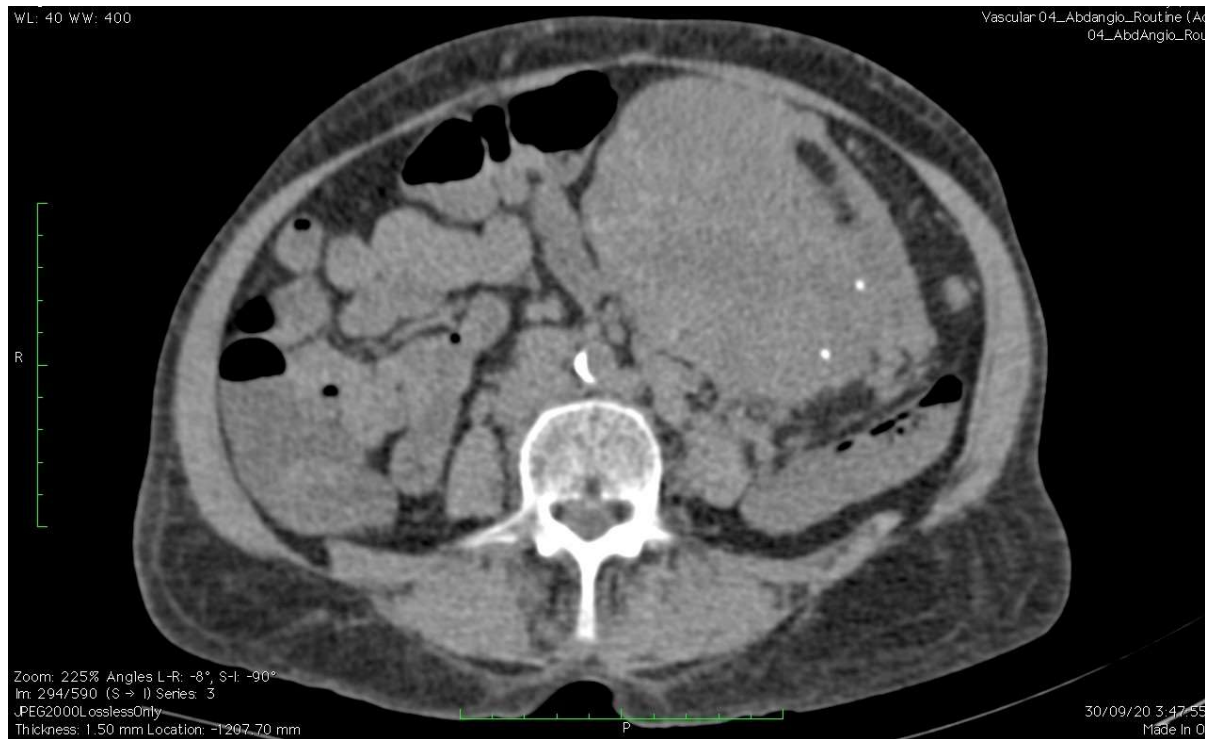On ultrasound abdomen and pelvis,

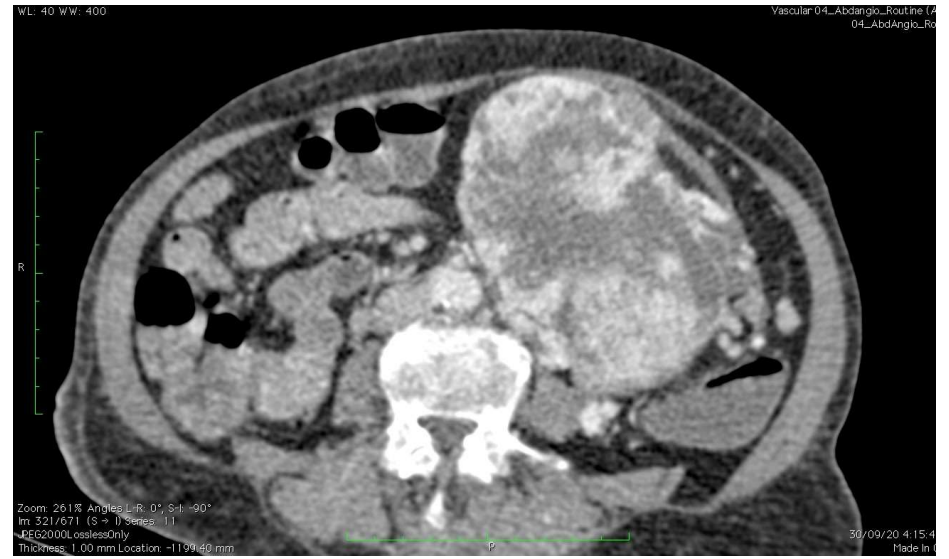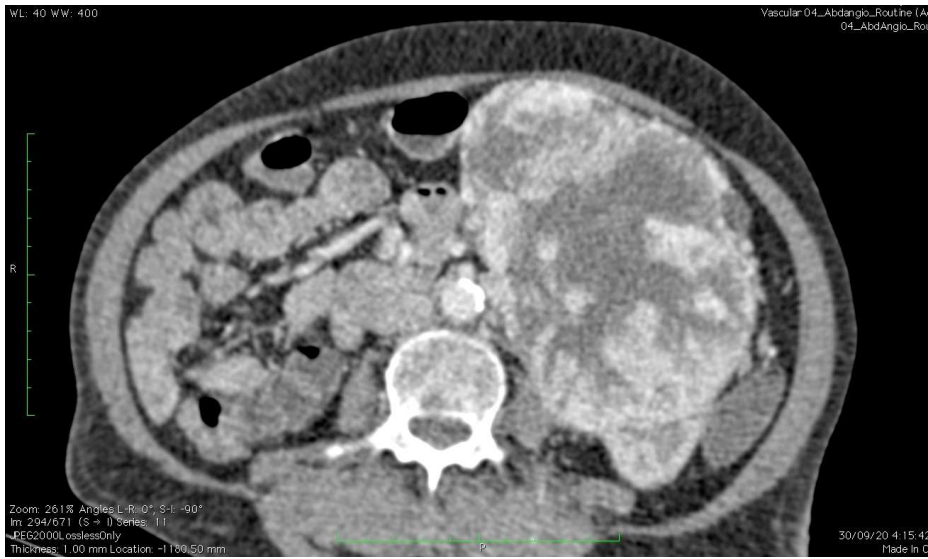

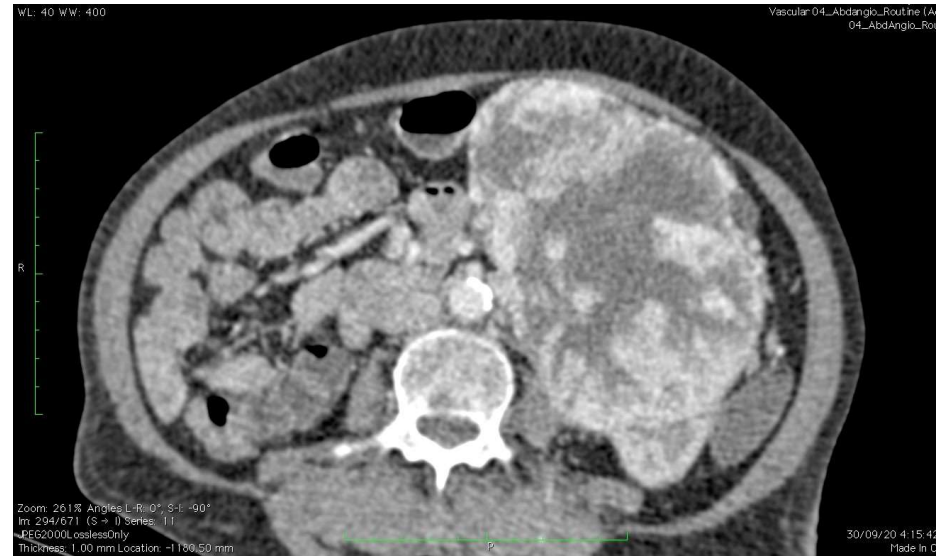
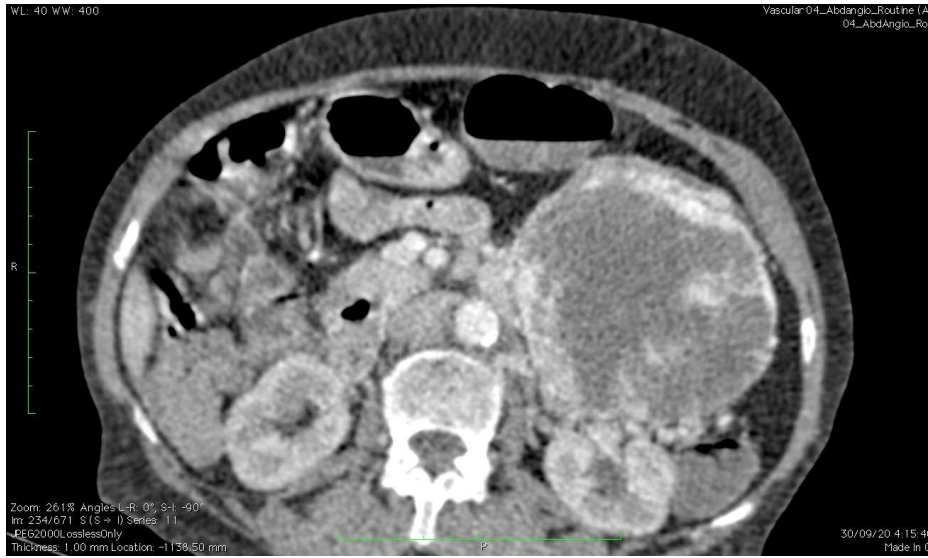

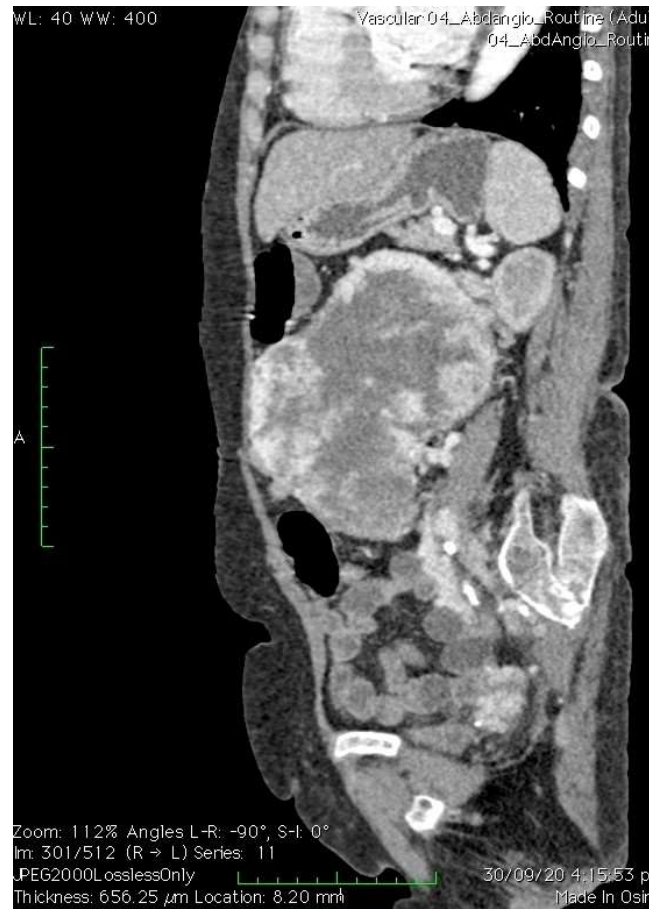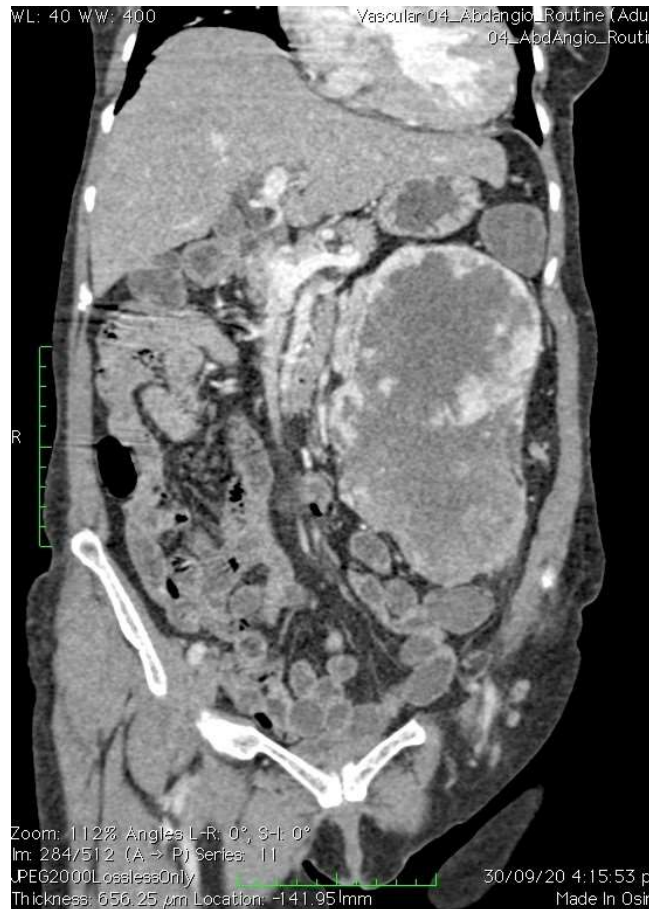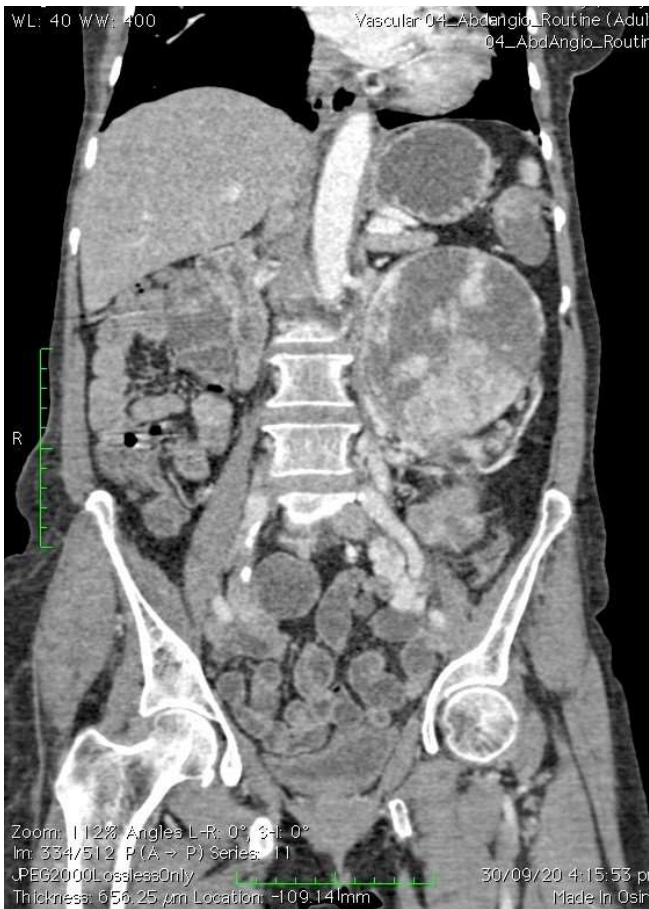- Large heterogeneously hypoechoic solid mass measuring 18 x 11 cm in the LIF and left para colic gutter reaching till the left hypochondriac. Mass is displacing the kidney posteriorly, spleen superiorly and bowel loops to the right side. Mass shows central necrosis and calcifications. There is increased peripheral vascularity in the tumor.
- IMPRESSION
  - Possibility of GIST/ Paraganglioma

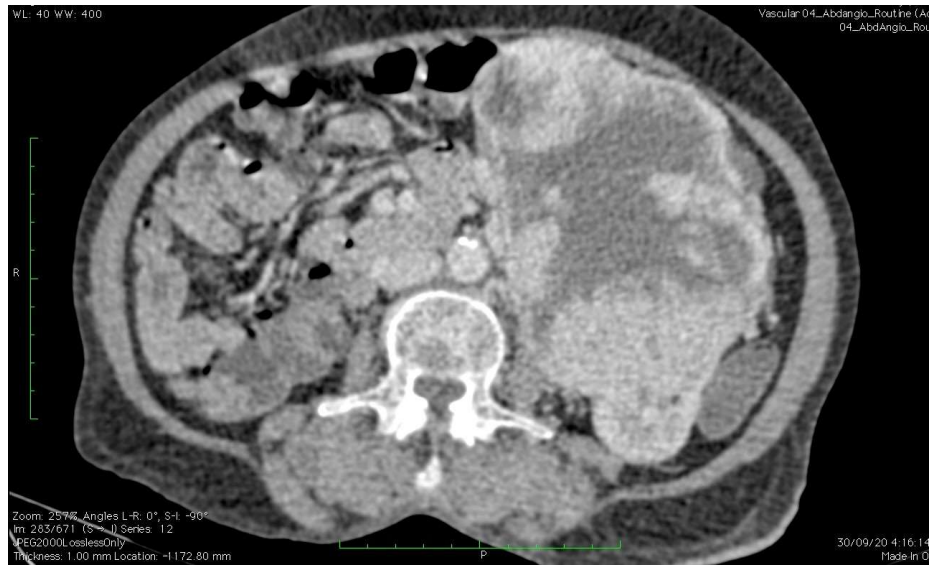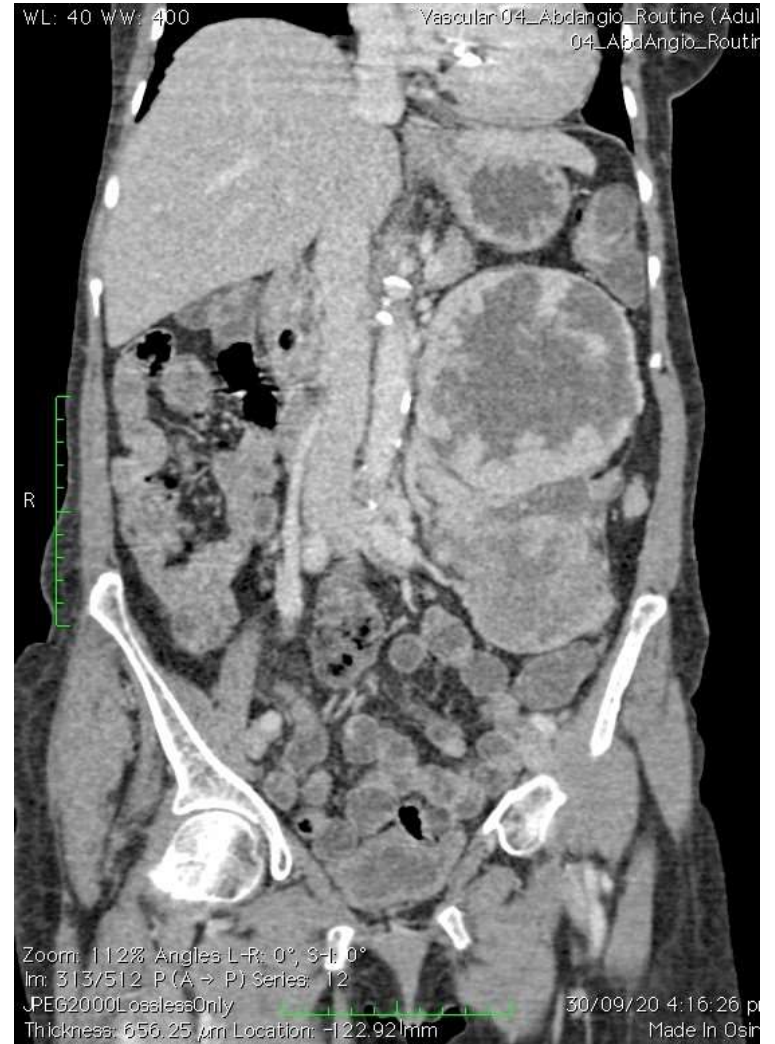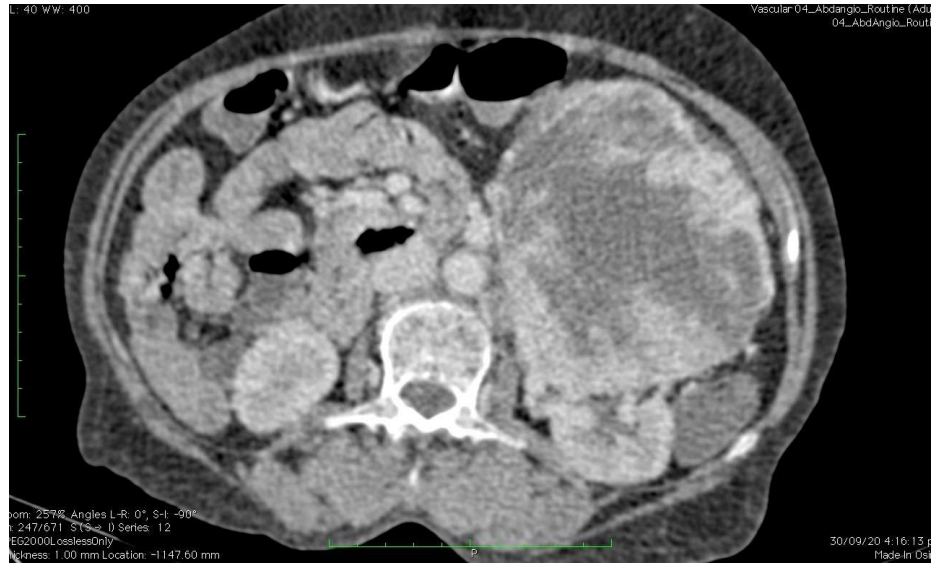# CT abdomen

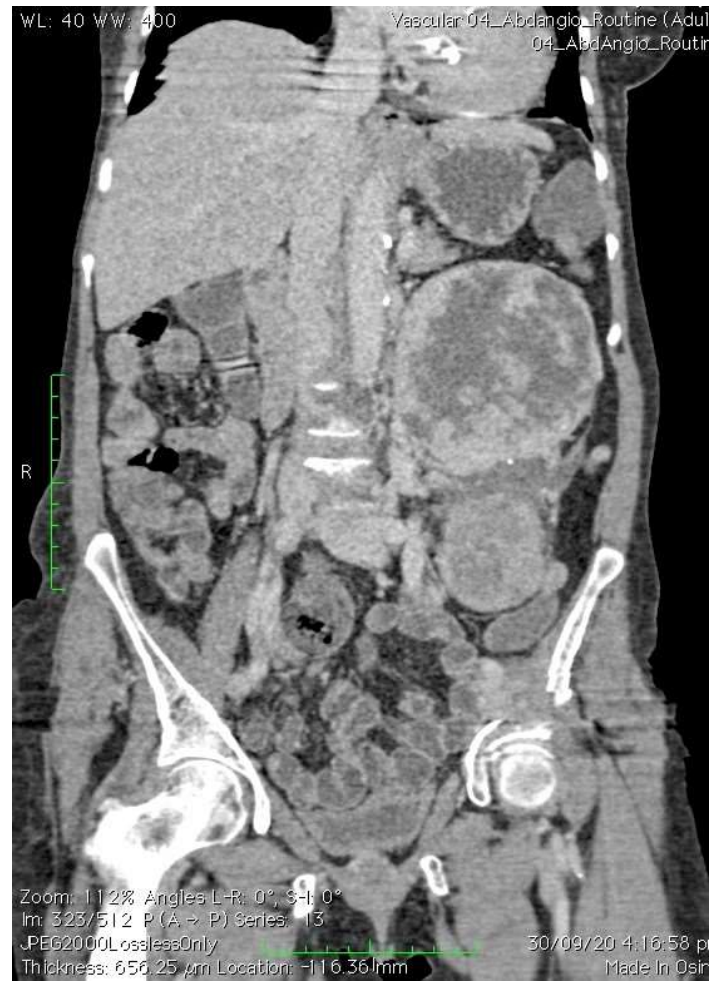
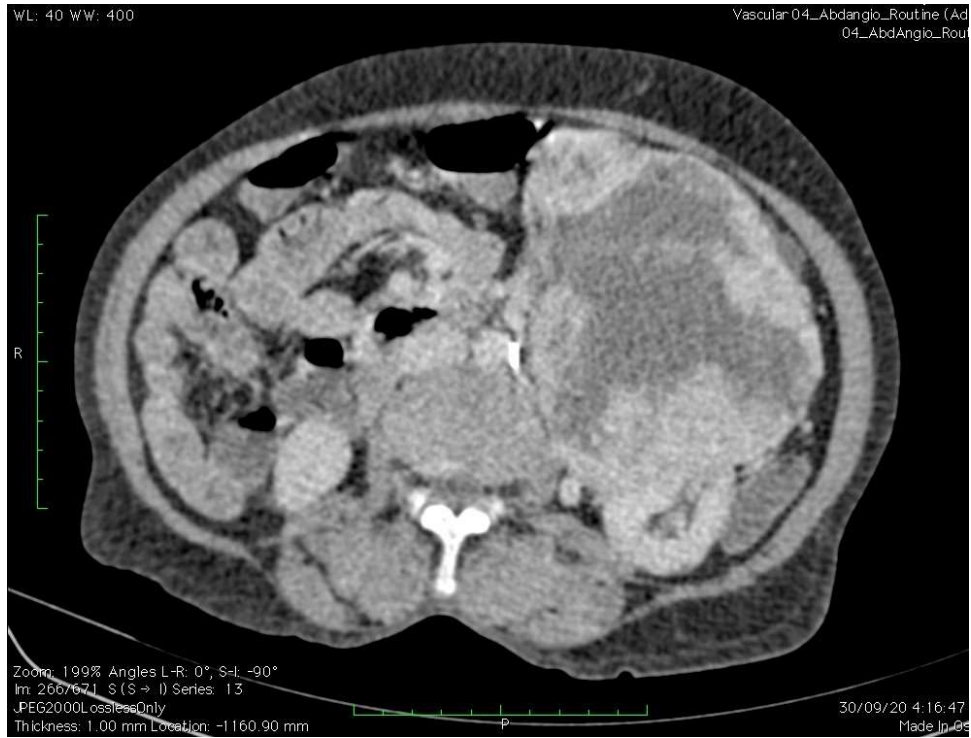










## CT IMPRESSION

- Large heterogenous intensely enhancing para aortic mass lesion with focal calcification & no infiltration into surrounding structures- extra-adrenal paraganglioma, more likely than GIST.

# DIFFERENTIALS

- PARAGANGLIOMA
- GIST
- PHEOCHROMOCYTOMA
- MESENCHYMAL TUMOURS